



**Shereen M. F. Gheith, MD, PhD**

**Chief, Section of Molecular Pathology**

**Department: Pathology & Laboratory Medicine**

**Division: Anatomic Pathology**

**Section: Hematopathology & Clinical Laboratory Medicine**

**Medical Training**

AIN Shams University School of Medicine, Cairo  
MBBCH - Bachelor of Science in Medicine and Surgery  
MSC - Master of Science in Clinical Pathology  
PhD - Doctor of Philosophy in Immunology

**Internship**

Transitional  
Presbyterian Medical Center of the Hospital of the University of Pennsylvania, Philadelphia, PA

**Residency**

Anatomic Pathology & Clinical Pathology  
Hospital of the University of Pennsylvania, Philadelphia, PA

**Fellowship**

Hematopathology  
Hospital of the University of Pennsylvania, Philadelphia, PA

**Board Certification(s):**

American Board of Pathology - Anatomic Pathology & Clinical Pathology  
American Board of Pathology - Hematology



**Health Network**  
LABORATORIES

**CENTER FOR ANATOMIC PATHOLOGY**

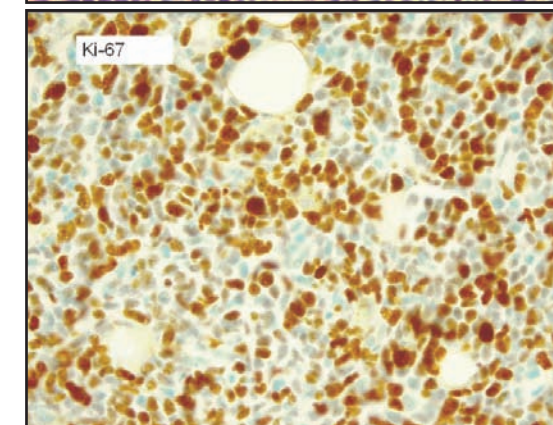
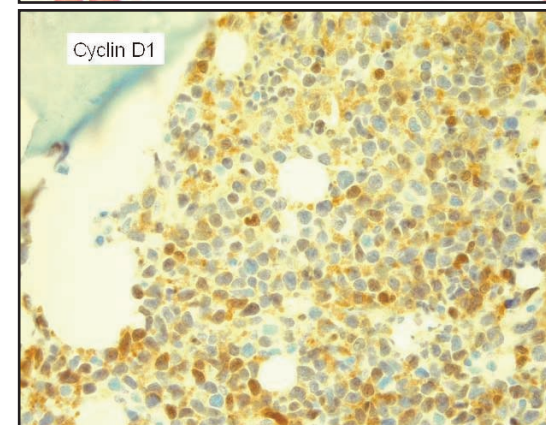
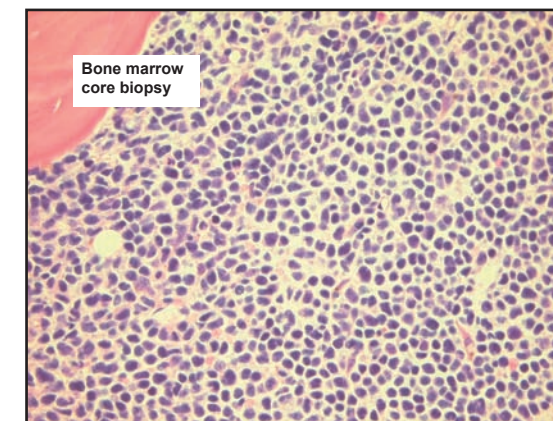
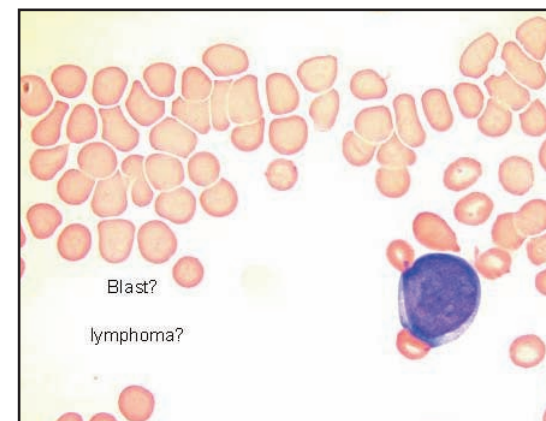
**Case History**

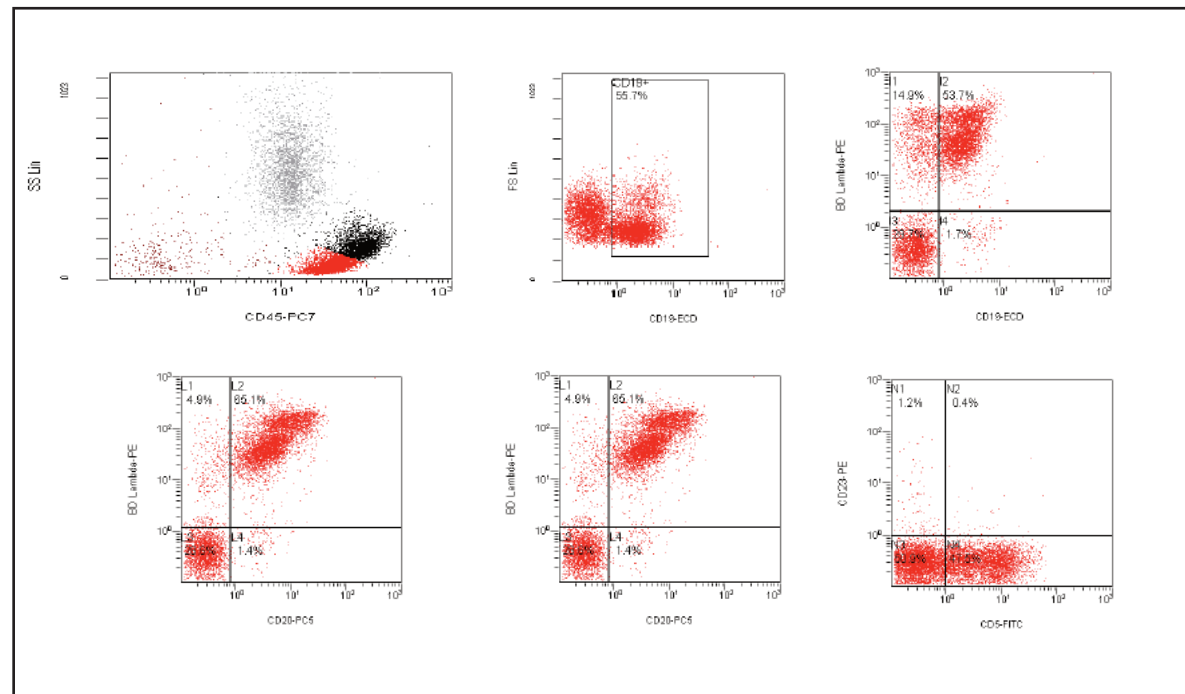
**Blastoid Mantle Cell Lymphoma, Pleomorphic Type**

**Shereen M. F. Gheith, MD, PhD**  
**Chief, Section of Molecular Pathology**  
**Department of Pathology & Laboratory Medicine**

Presenting Case

- An 83-year-old gentleman who presented for:
  - progressive shortness of breath
- His cardiologist ordered a CBC:
  - WBC of 17.5 THOU/CMM
  - hemoglobin and hematocrit of 8.7g/dL and 24.5%
  - platelet count of 28 THOU/CMM
- Past Medical History:
  - bladder cancer 40 years prior, status post XRT and BCG treatment
  - history of melanoma 30 years prior
  - a kidney mass of unknown etiology since the year 2000
  - History of hypertension, hyperlipidemia, and hypothyroidism; coronary artery disease status post stents





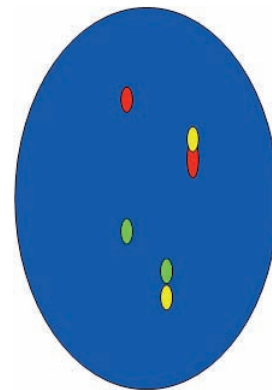
## Cytogenetics & Molecular Studies

### • **Cytogenetic Studies:**

- A normal (46,XY) male chromosome complement was observed in all 20 cells analyzed

### • **Molecular (FISH):**

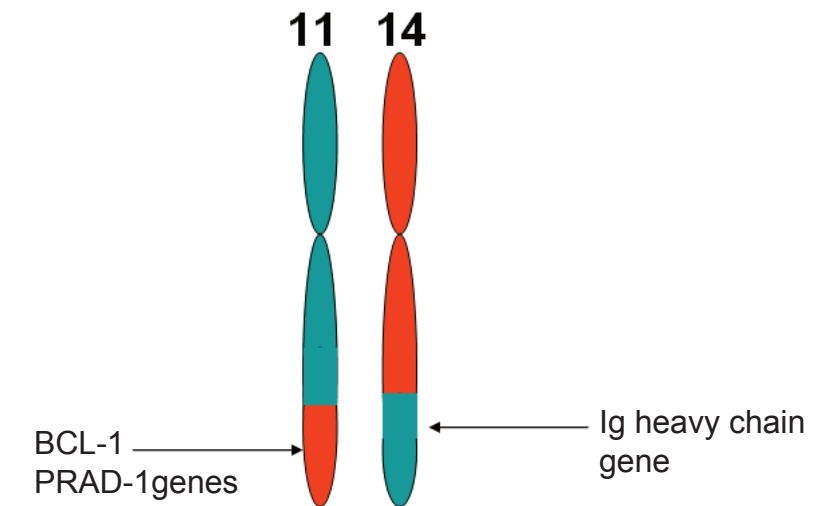
- Positive for a CCND1/IgH gene rearrangement
- Positive for gain of:
  - 12, 11q, 13q, and 14q
- Positive for deletion of:
  - 13q and 17p
  - 19 cells showed a deletion for the p53 gene on chromosome 17



FISH of t(11;14): BCL1 (red signal), IgH (green signal). Red/yellow and green/yellow represent the fusion signal in MCL.

*CT scan of the chest, abdomen, and pelvis showed retroperitoneal and mesenteric lymphadenopathy, bilateral inguinal lymphadenopathy and small mediastinal lymph nodes.*

## Mantle Cell Lymphoma and t(11;14) Chromosome



MCL	Blastoid MCL
<ul style="list-style-type: none"> <li>• Is a distinctive type of non-Hodgkin's lymphoma composed of small- to medium-sized lymphocytes that coexpress CD5</li> <li>• The chromosome translocation t(11;14)(q13;q32) results in activation of the cyclin-D1 gene</li> <li>• Histologic variants: mantle zone, nodular and diffuse</li> <li>• Despite its histologic resemblance to low-grade B-cell lymphomas, MCL is an aggressive disease with a poor prognosis</li> </ul>	<ul style="list-style-type: none"> <li>• A histologically more aggressive form of MCL</li> <li>• Occurs, either de novo or in patients with typical MCL</li> <li>• Two types of blastoid MCL are described:               <ul style="list-style-type: none"> <li>– classic type: lymphoblast- like</li> <li>– pleomorphic type</li> </ul> </li> </ul>

### Diagnosis:

*A perfect example of an uncommon entity: blastoid mantle cell lymphoma, pleomorphic type*